

Results of Calcaneal Osteotomy & Flexor Digitorum Longus transfer in Stage II Acquired Flatfoot Deformity

Mr Amit Chauhan

Mr Prasad Karpe

Ms Maire-claire Killen

Mr Rajiv Limaye

University Hospital of North Tees and Hartlepool, United Kingdom

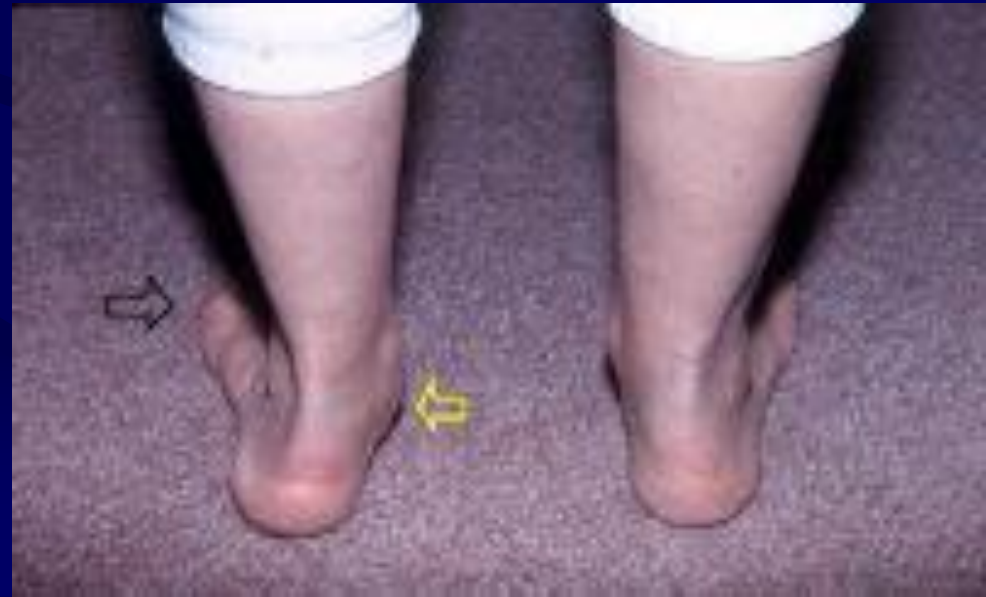Introduction

Acquired flat foot - common problem between 45- 60 years

Loss of medial arch - collapse of foot & flattening

Women affected more

Multi-factorial causes



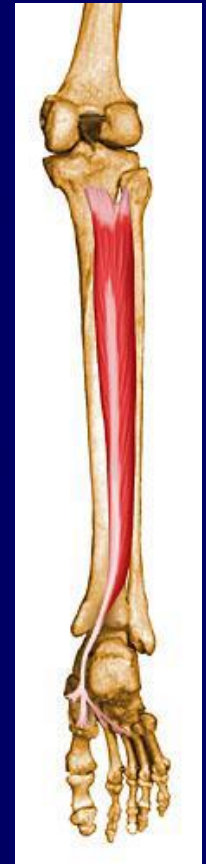Causes of acquired flat feet (Adult)

- Posterior tibial tendon dysfunction
- Sub-talar arthritis
- Mal-united calcaneal fractures
- Tarsal coalition
- Tarsal tunnel syndrome

- Could be flexible or fixed.

Anatomy - Posterior Tibial Tendon

- Origin- Interosseous membrane & adjacent surfaces of tibia & fibula
- Part of deep posterior compartment of calf
- Tendon forms in distal third calf
- Behind medial malleolus
- Area of relative hypovascularity
- Has very broad insertion in foot



Posterior Tibial Tendon

- Axis posterior to ankle & medial to sub-talar joint
- Ankle plantar flexor
- Sub-talar invertor
- Forefoot adductor
- Elevation of medial arch
- Locks transverse tarsal joints, rigid lever for toe-off phase

Causes of deformity

- Relative hypo-vascularity
-
- Sharp angle turn of tendon behind medial malleolus
- Involvement of synovium at early stage & limited space

Pathogenesis of deformity

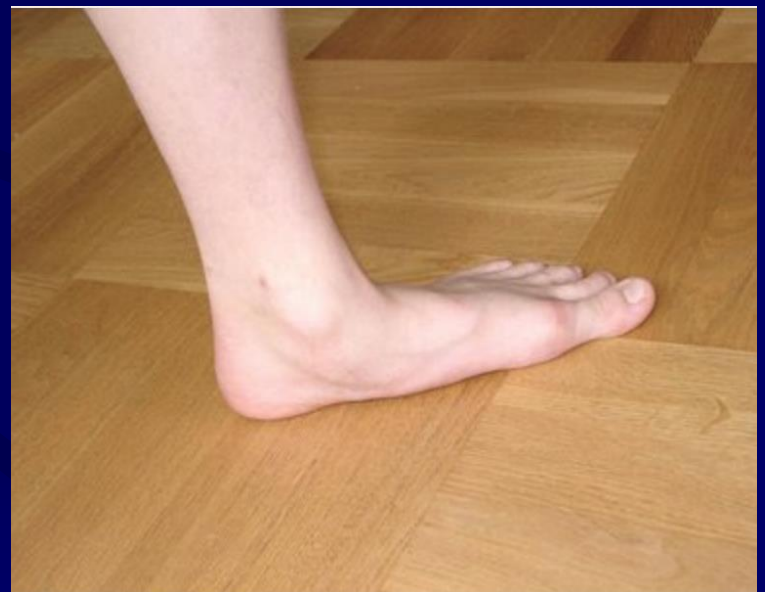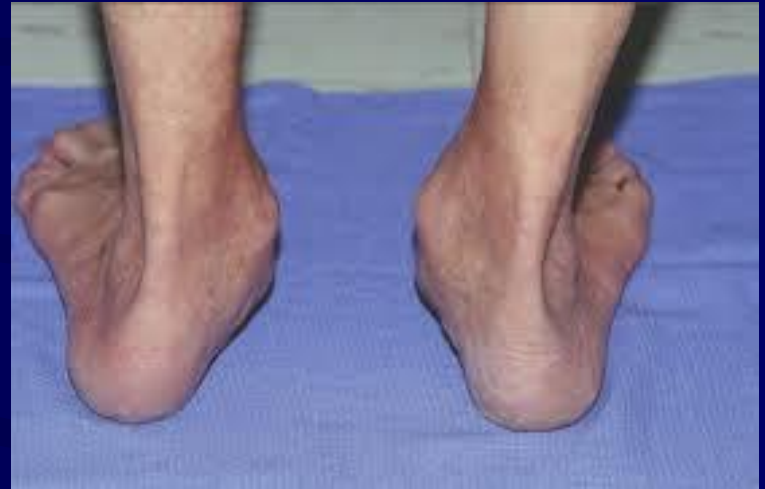- No primary inversion
- Achilles lies lateral to subtalar joint; progressively shorten and tight
- Heel valgus
- Attenuation of spring ligament
- Midfoot abduction; forefoot supination
- Loss of arch; increased load on 1st MT

Pathological findings

- Synovitis & hypovascularity
- Degenerative micro-tears initially
- Stretching & attenuation of tendon
- Further macroscopic tears
- Loss of arch- flat foot
- Sub-talar joint arthritis

Symptoms

- Pain
- Deformity
- Loss of medial arch
- “Too many toes” sign
- Achilles contracture-
Hindfoot valgus





Single-limb heel rise

Investigations

- Radiographs- AP & LATERAL weight bearing
- MRI
- Ultrasound

Classification

Johnson and Strom (1989)

- Stage 1- tenosynovitis- normal length
- Stage 2- Flexible hind foot valgus- further sub divided
- Stage 3- rigid hind-foot valgus
- Stage 4- ankle valgus (Myerson 1996)

Johnson KA, Strom DE. Tibialis posterior tendon dysfunction. Clin Orthop Relat Res 1989;239:196–206.

Stage II

- Various treatment options depending on stage
- Medial displacement calcaneal osteotomy(MDCO)
- MDCO with Flexor digitorum longus(FDL) transfer
- Lengthening of lateral column
- Gastrocnemius slide

- Used alone or in combinations

Our Study

- Retrospective study (2012 to 2015)
- 23 patients with symptomatic stage II flexible AFFD
- Medial sliding calcaneal osteotomy and FDL transfer

Methodology

- Inclusion criteria

- Asymmetrical flexible flat foot deformity
- Pain and swelling on medial aspect of ankle
- Single heel raise test positive
- Reduced/ Absent strength of inversion (MRC < grade 2),
with mobile hind-foot

Methodology

- Exclusion Criteria

- Infection
- Diabetes
- Hindfoot arthritis
- Neuroarthropathy

Methodology

- Failed conservative management for 6 months
- MRI confirmation
- Combined medial slide calcaneal osteotomy along with FDL transfer
- Manchester Oxford Foot Questionnaire (MOXFQ) scoring Preop & Postop
- Follow up 2 wks(ROS), 6 weeks & later at 3, 6, and 12 months

Manchester-Oxford Foot Questionnaire

- Established validated patient-reported outcome measure for foot and ankle Surgery
- Comprise three subscales: Pain, walking/standing and social interaction

Manchester-Oxford Foot Questionnaire

- 16-item questionnaire
- Answers on five-point Likert scale
- Each item scored from 0-4

None of the time(0)

Rarely(1)

Some of the time(2)

Most of the time(3)

All of the time(4)

MOXFQ contd.

- Three subscales:
 - Pain(5 questions)
 - Walking/standing problems(7 questions)
 - Social interaction(4 questions)
- Raw scale scores converted to metric from 0 to 100

Morley, D., Jenkinson, C., Doll, H., Lavis, G., Sharp, R., Cooke, P. and Dawson, J., 2013. The Manchester–Oxford Foot Questionnaire (MOXFQ). *Bone and Joint Research*, 2(4), pp.66-69.

MOXFQ contd.

- Single index score calculated.. elaborate

$100 / \text{max. possible score} \times \text{Actual score}$

Surgical steps

- Supine with sandbag under ipsilateral buttock
- Osteotomy performed before FDL transfer
- Oblique incision made behind & approximately 2 cm distal to lateral malleolus, taking care of *sural nerve*

- Osteotomy is performed 45° to sole
- Distal segment of calcaneum displaced medially for 1 cm
- Held by cannulated, partially-threaded, 6.5 mm cancellous screw
- Lateral wound closed & sandbag removed
- Medial incision made along line of Posterior tibial tendon & extended distally to expose tendon of FDL

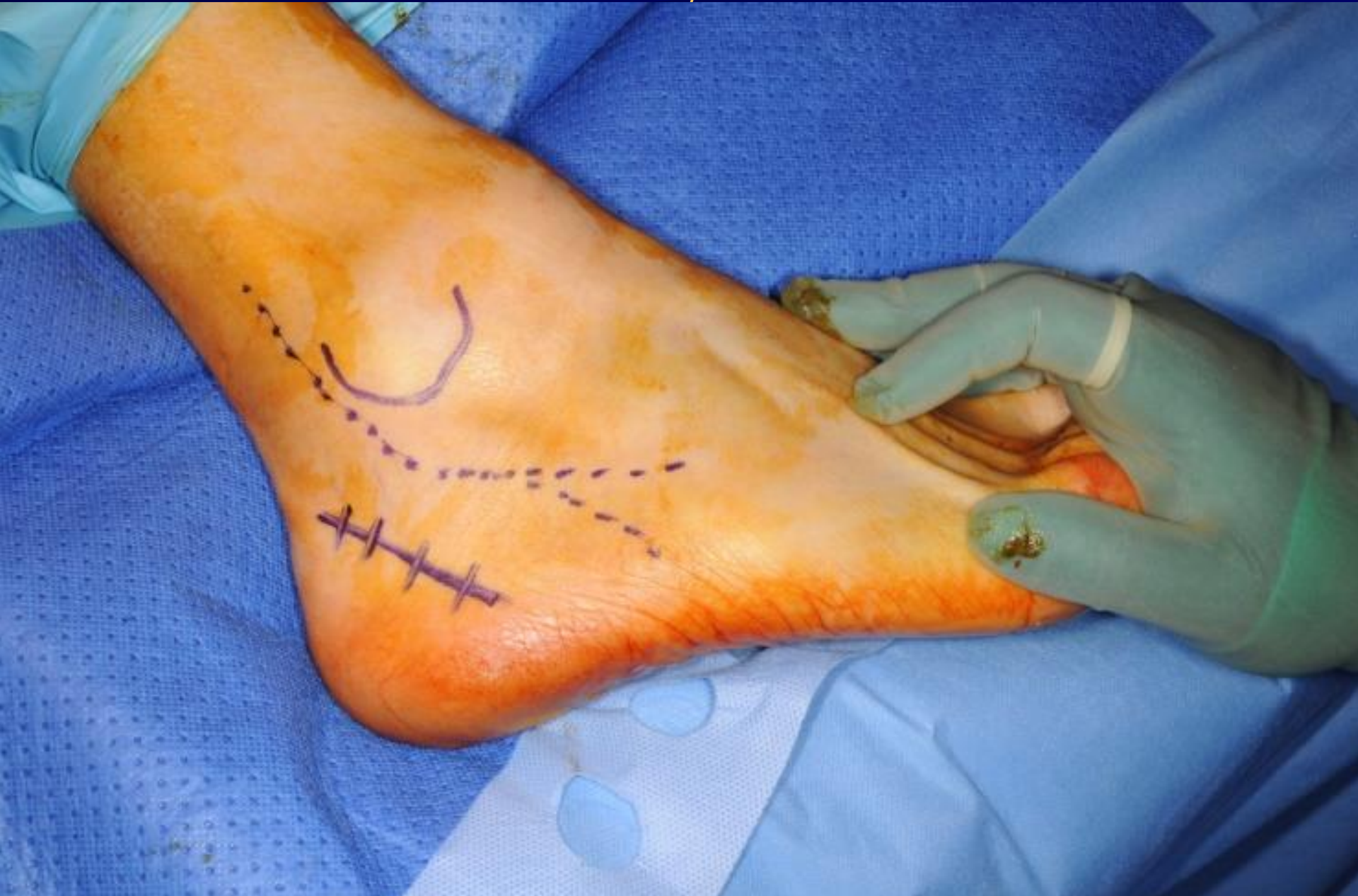- Diseased PTT is excised
- FDL is harvested up to knot of Henry & divided distally
- 4.5 mm drill hole in navicular & FDL rerouted through navicular from plantar to dorsal
- Sutured back on itself using No.2 Ethibond keeping adequate tension and foot in inversion

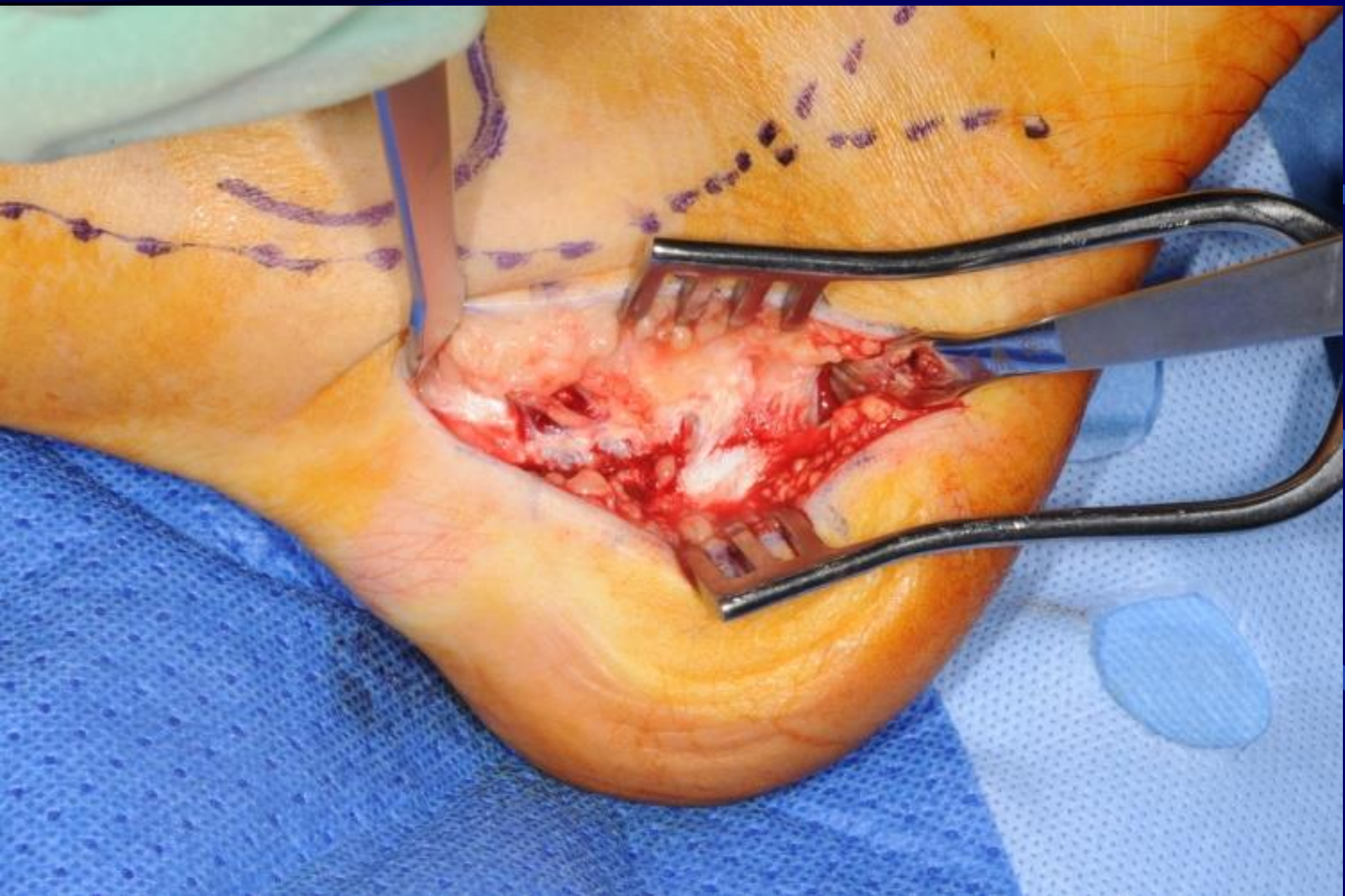
- Wound closure, back slab in moderate equinus and varus for 2 weeks
- At 2 weeks – Removal of stitches
- Below-knee fibrecast applied in neutral position for further four weeks
- At 6 weeks, air cast boot applied and physio started

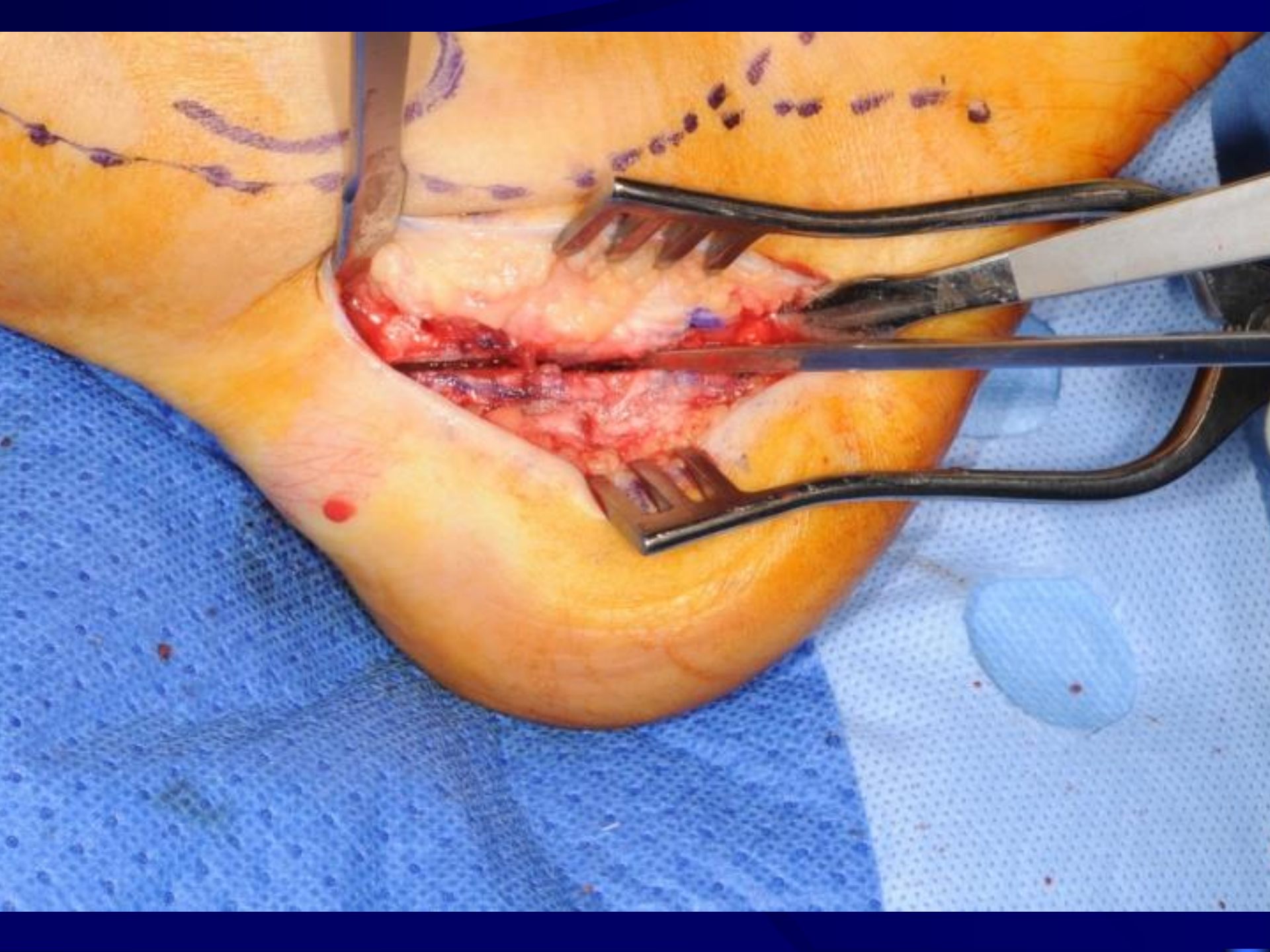Post op

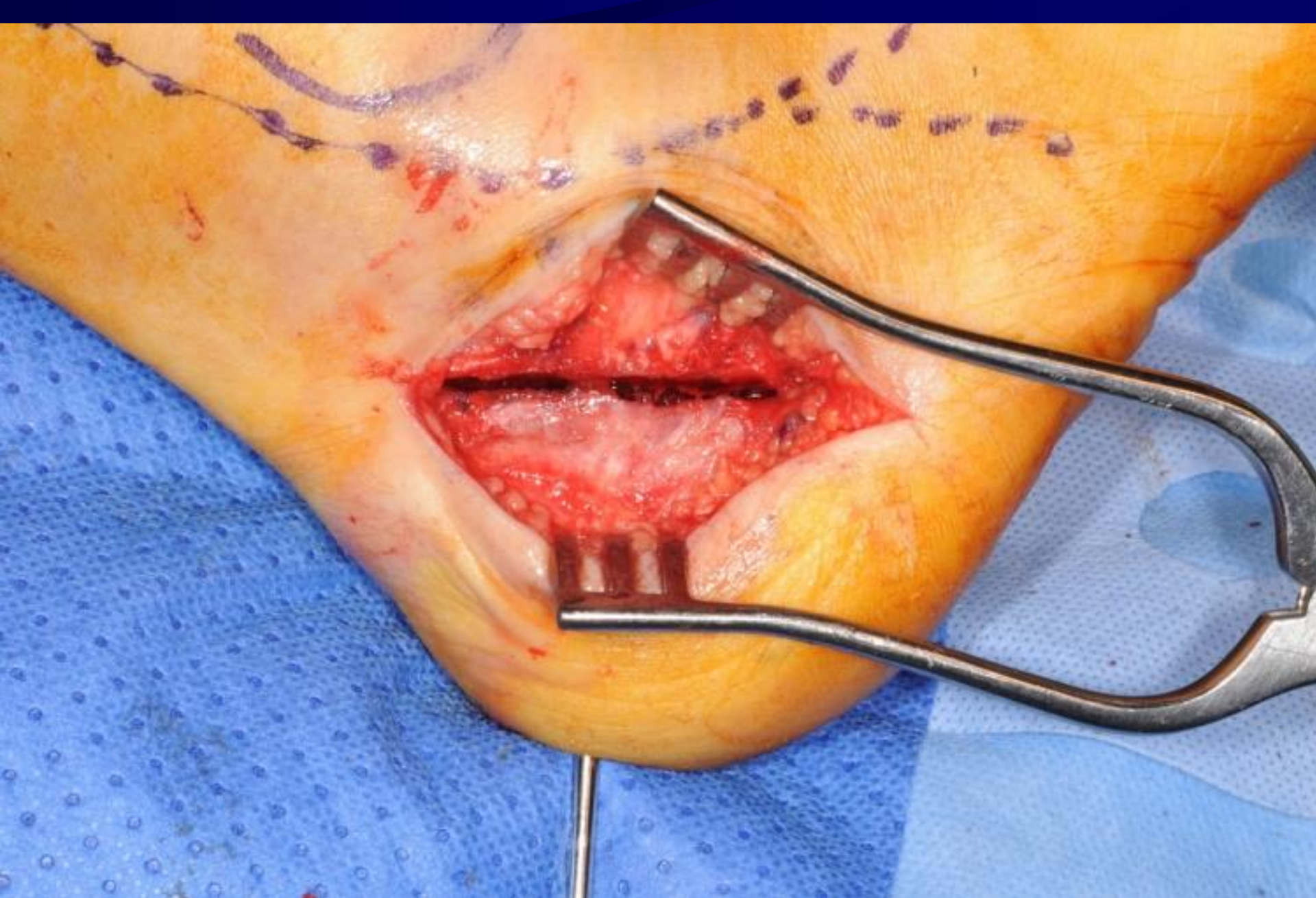- Non-weight-bearing for six weeks
- At 6 weeks – cast off, X-rays
- Weight bearing as pain allows, physiotherapy
- Follow up: 3,6,12 months and scoring at 6 and 12 months

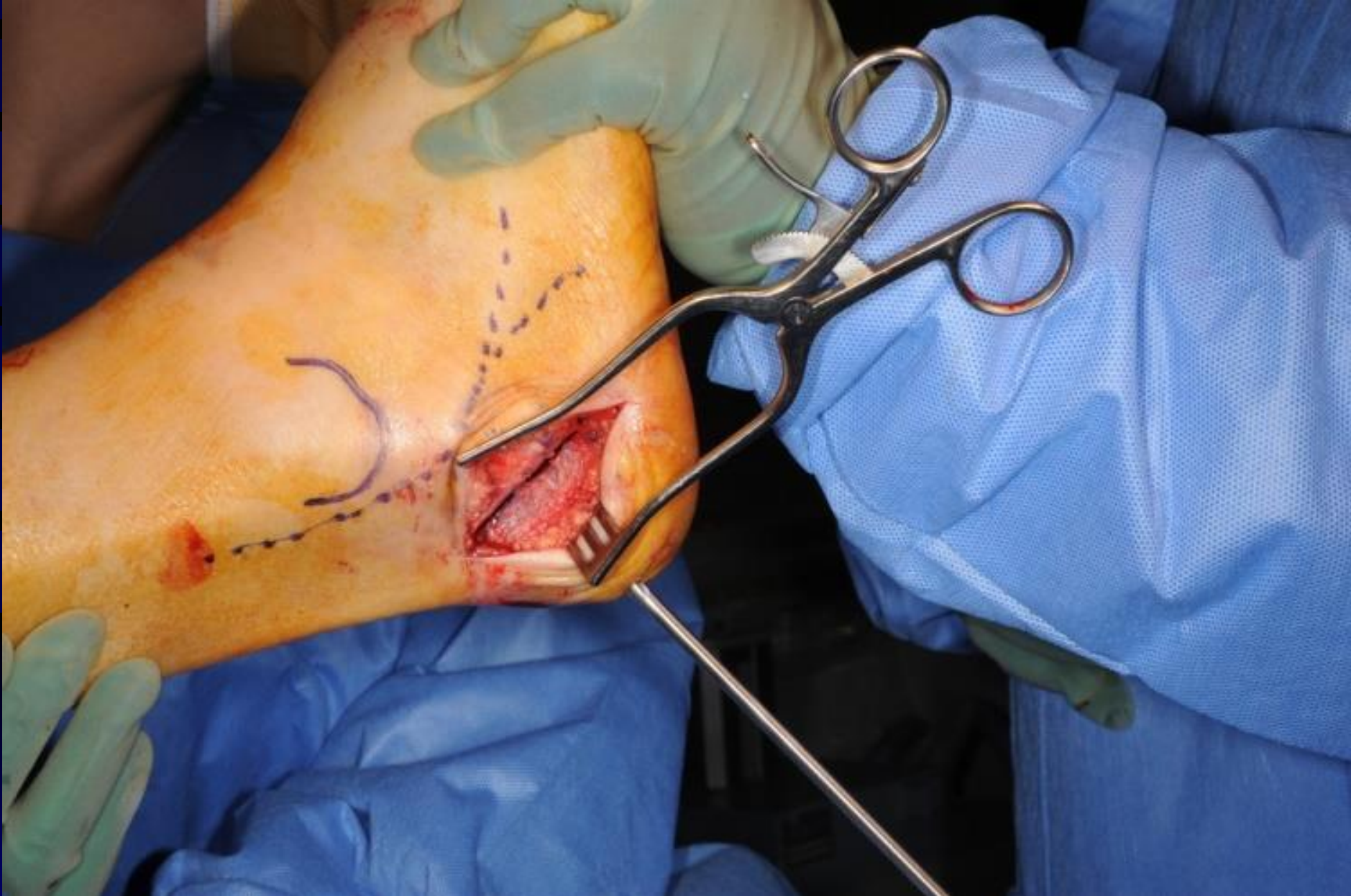
Calcaneal osteotomy and FDL Transfer

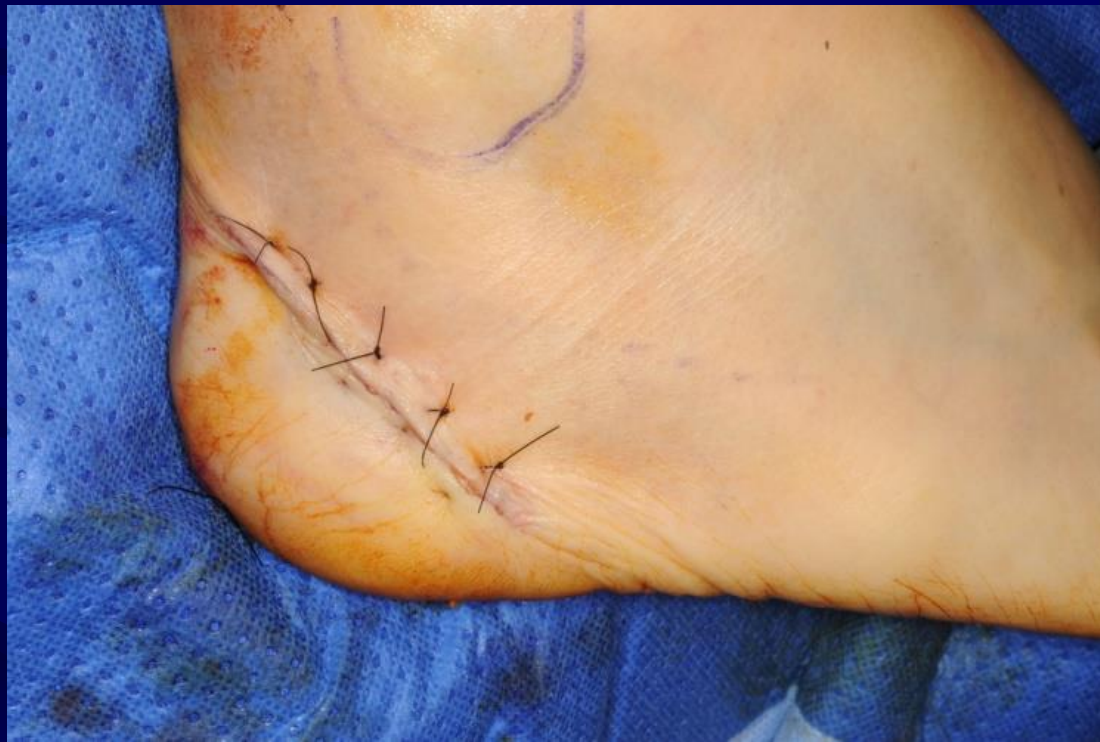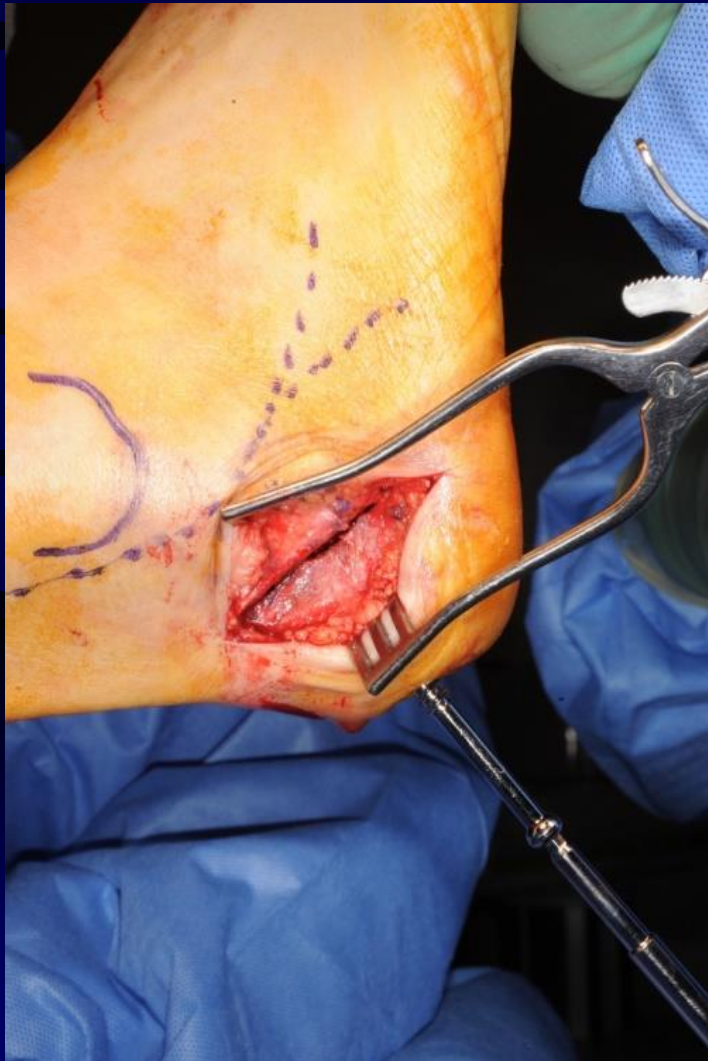



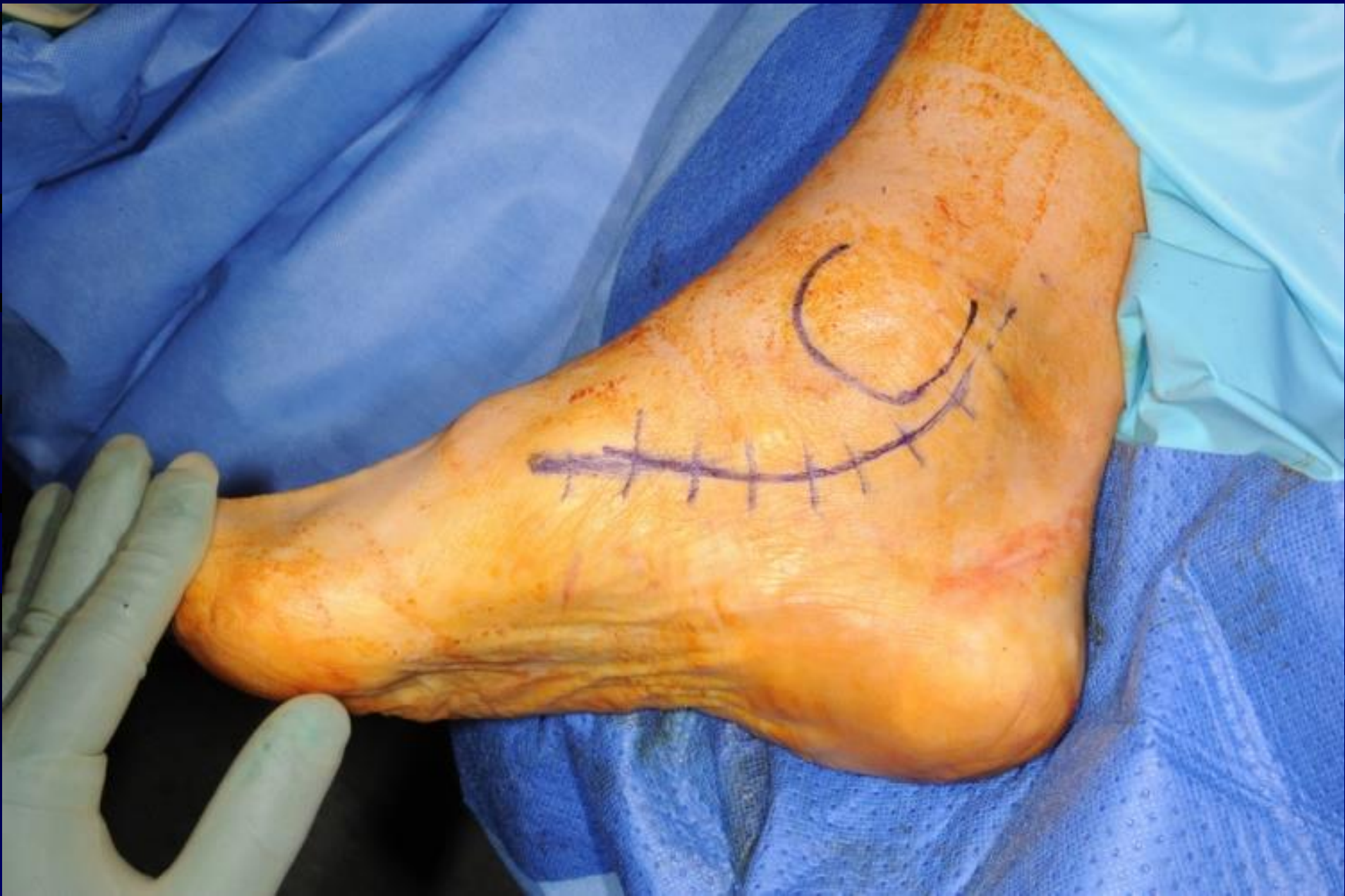


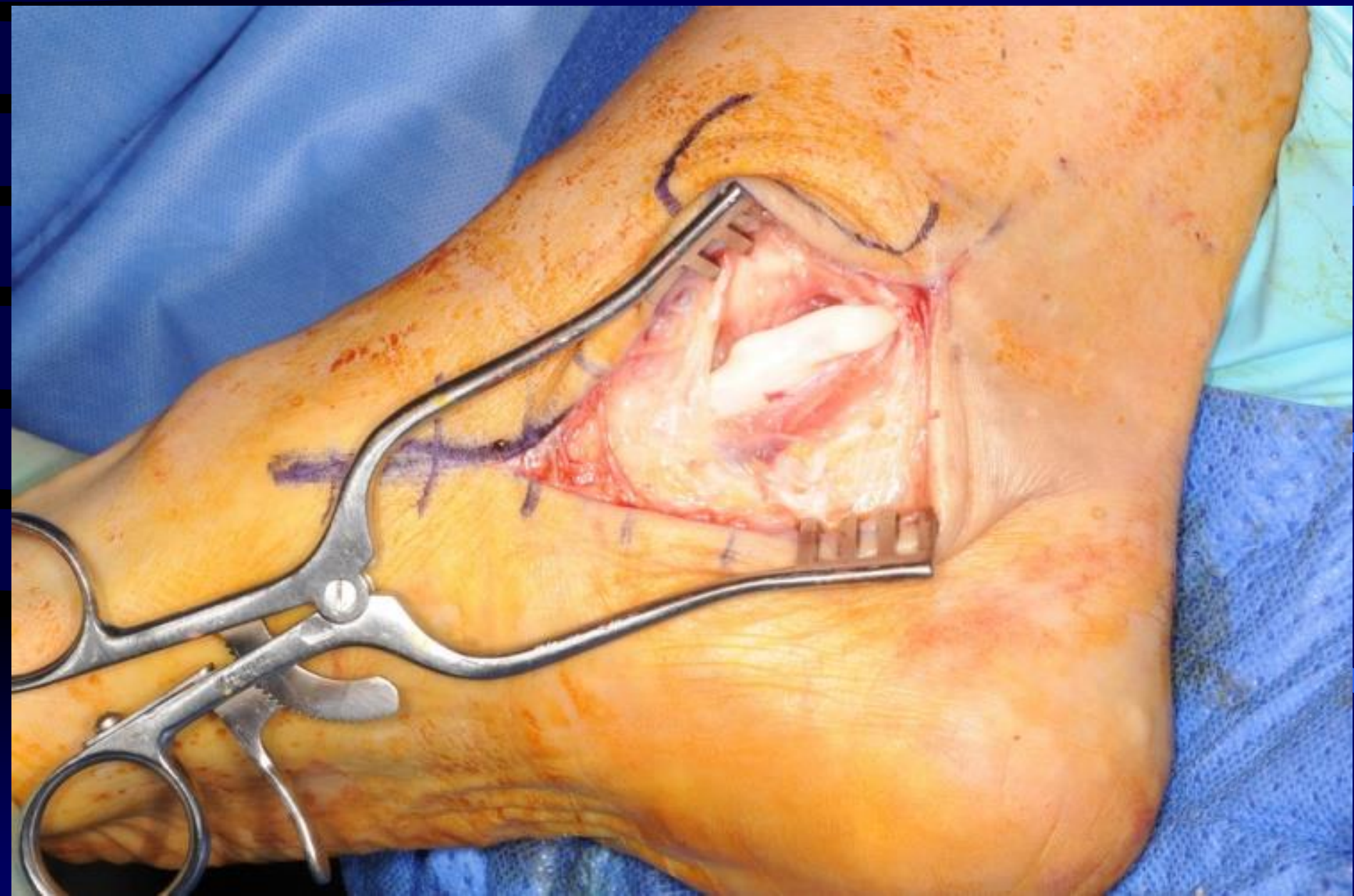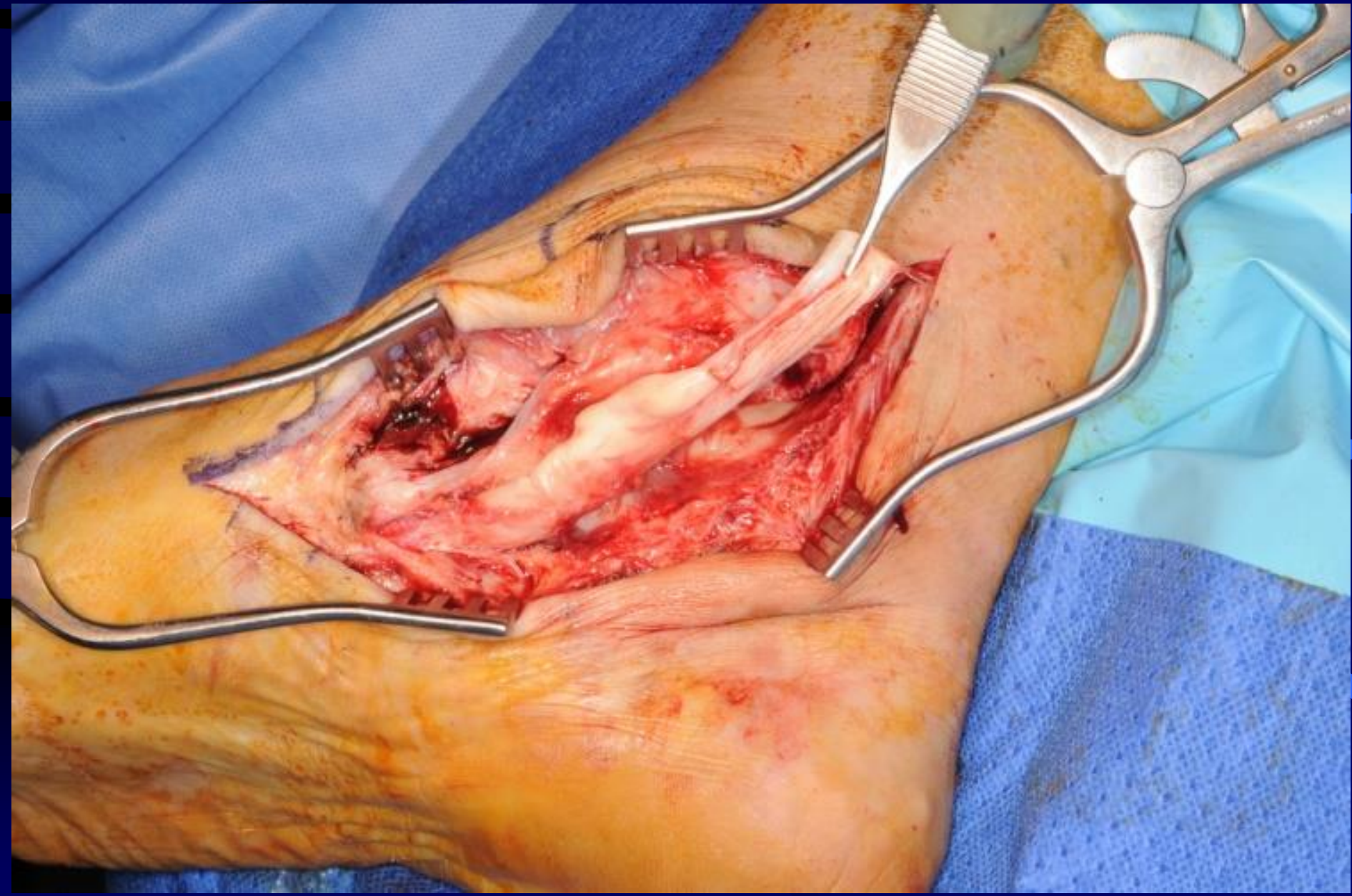













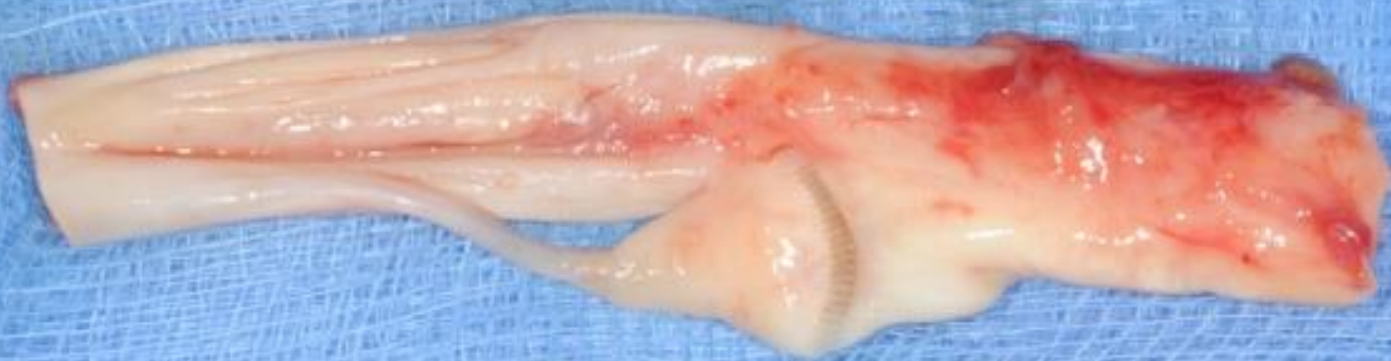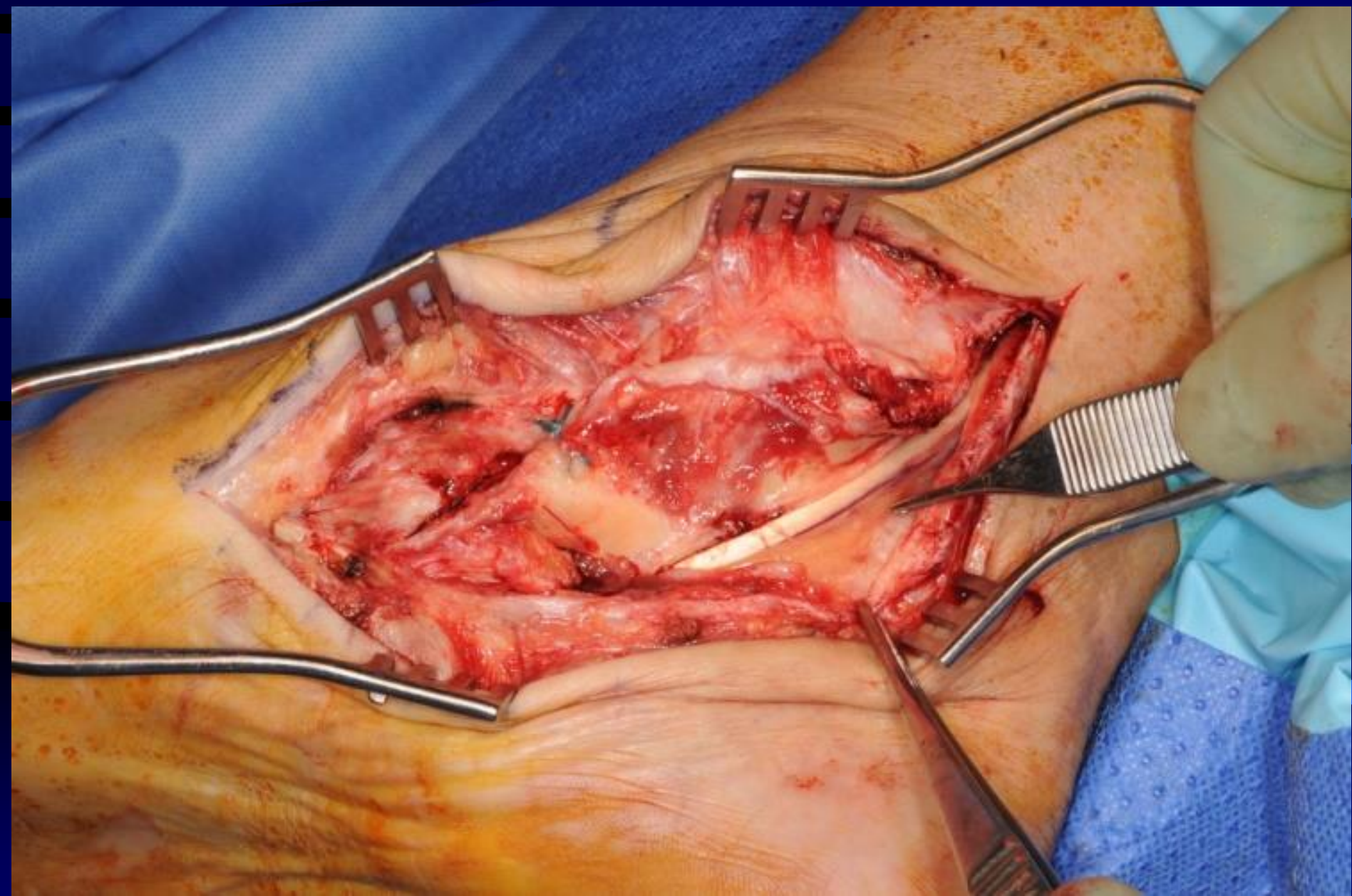


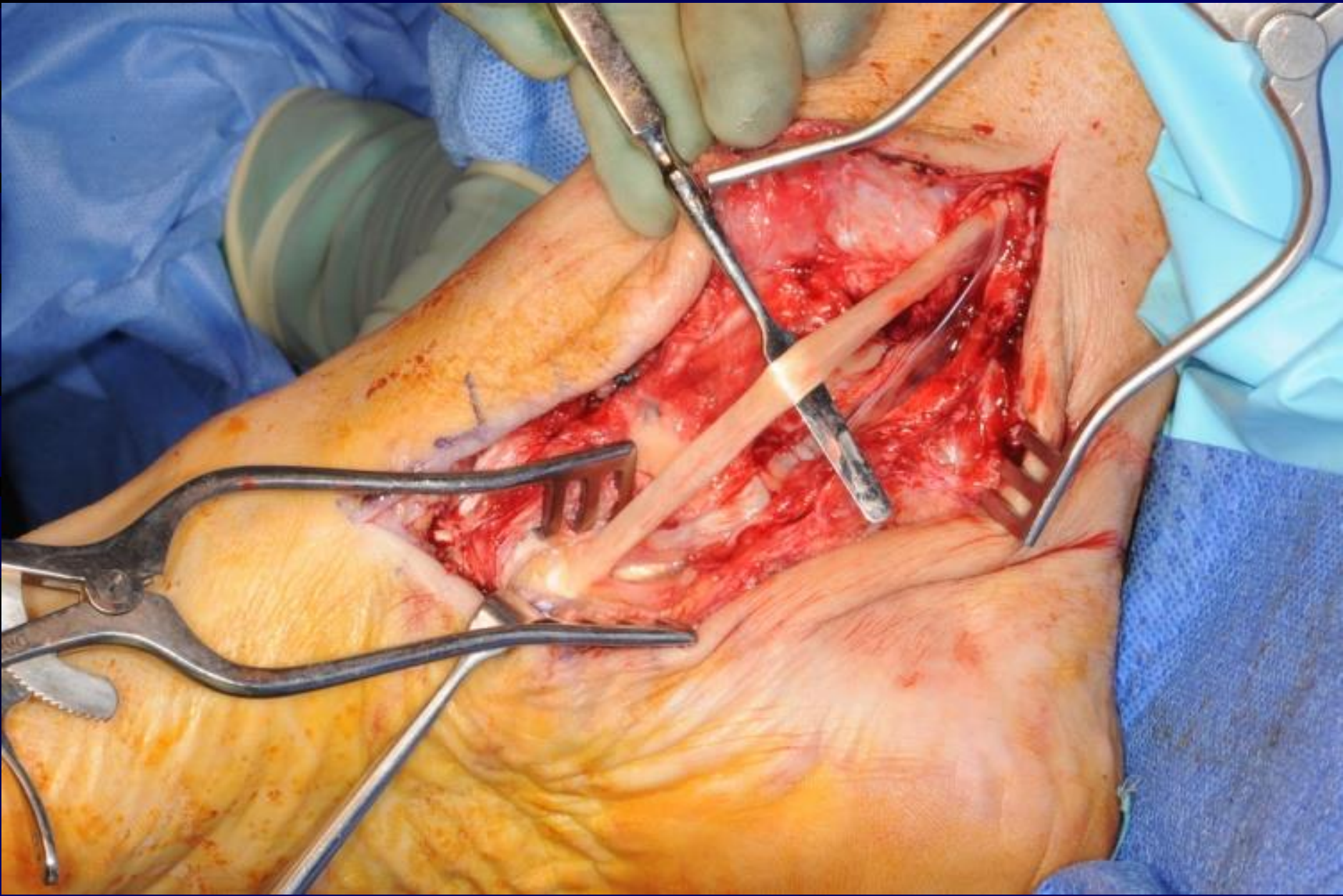
Universal

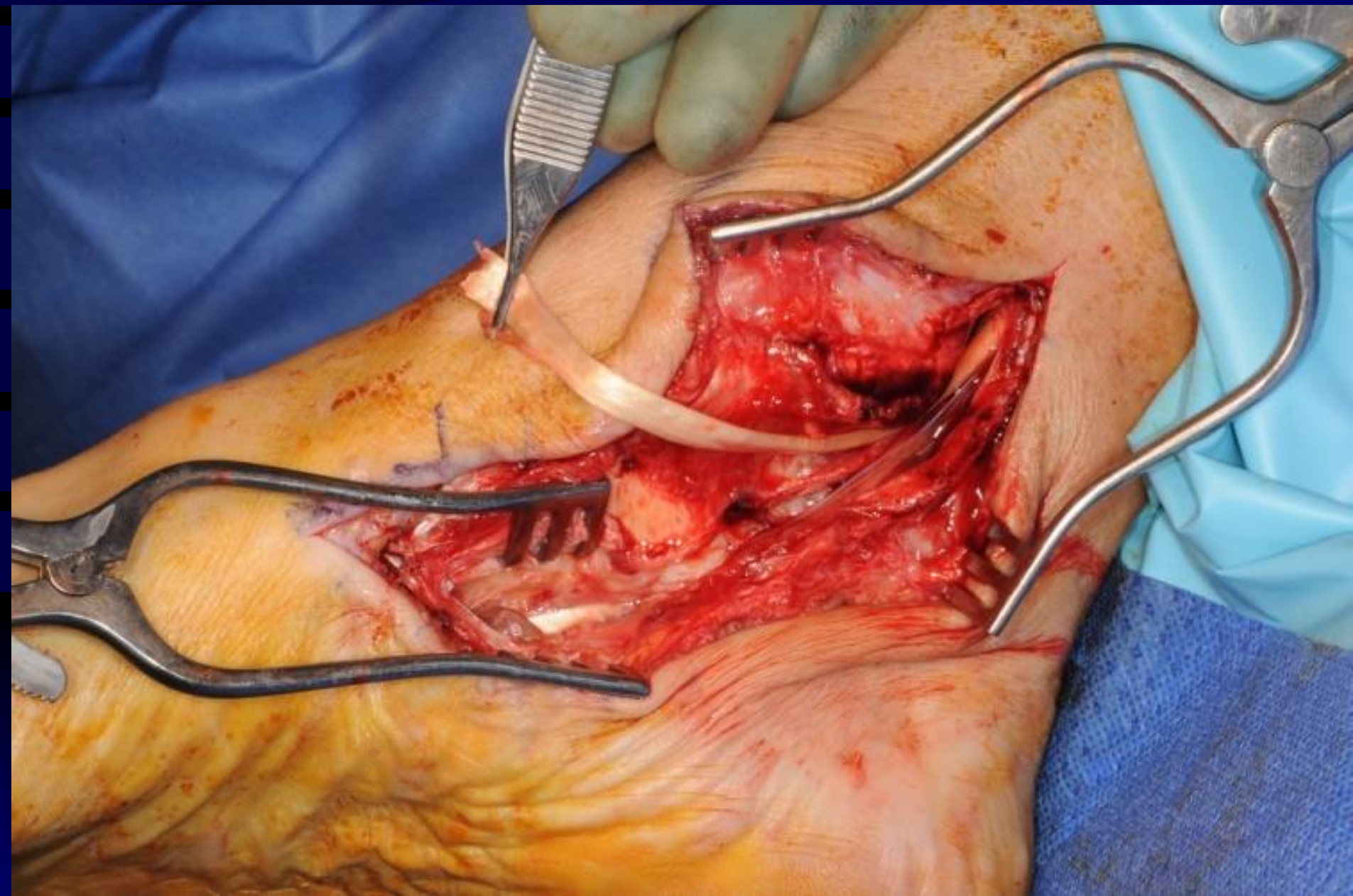
Shermond

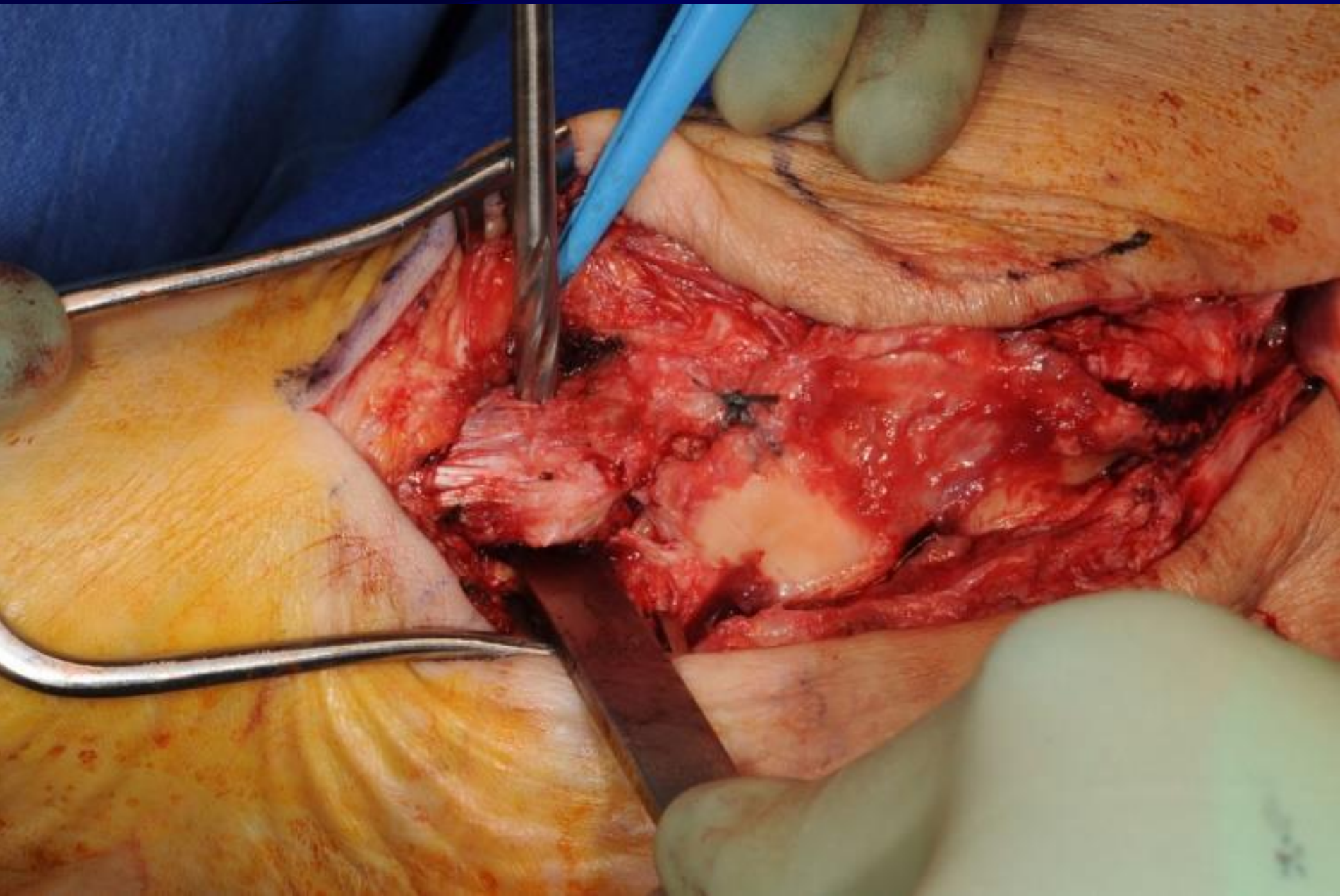
Bunzl Retail & Healthcare Supplies Ltd
Millmarsh Lane, Enfield, Middlesex, EN

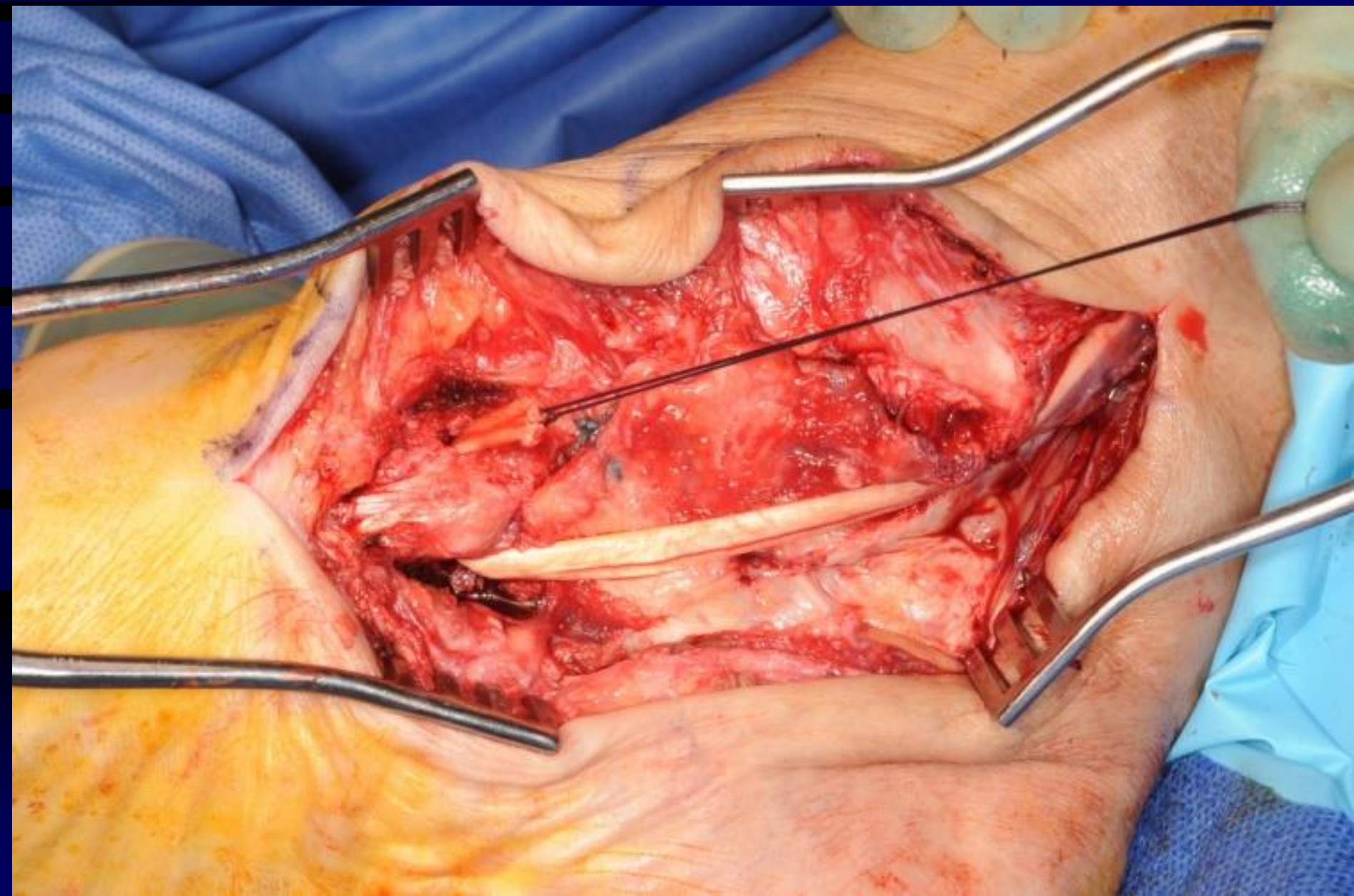


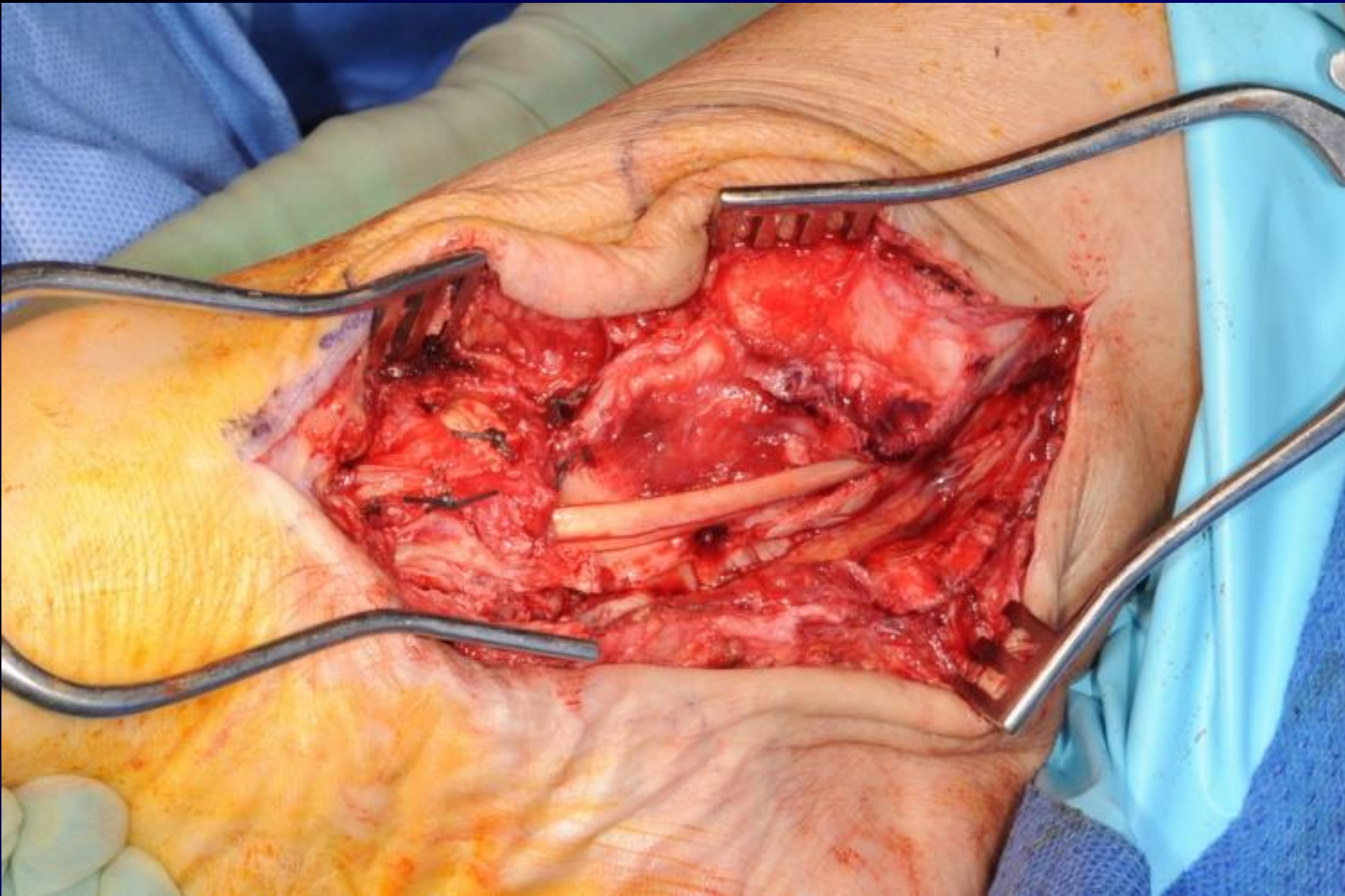


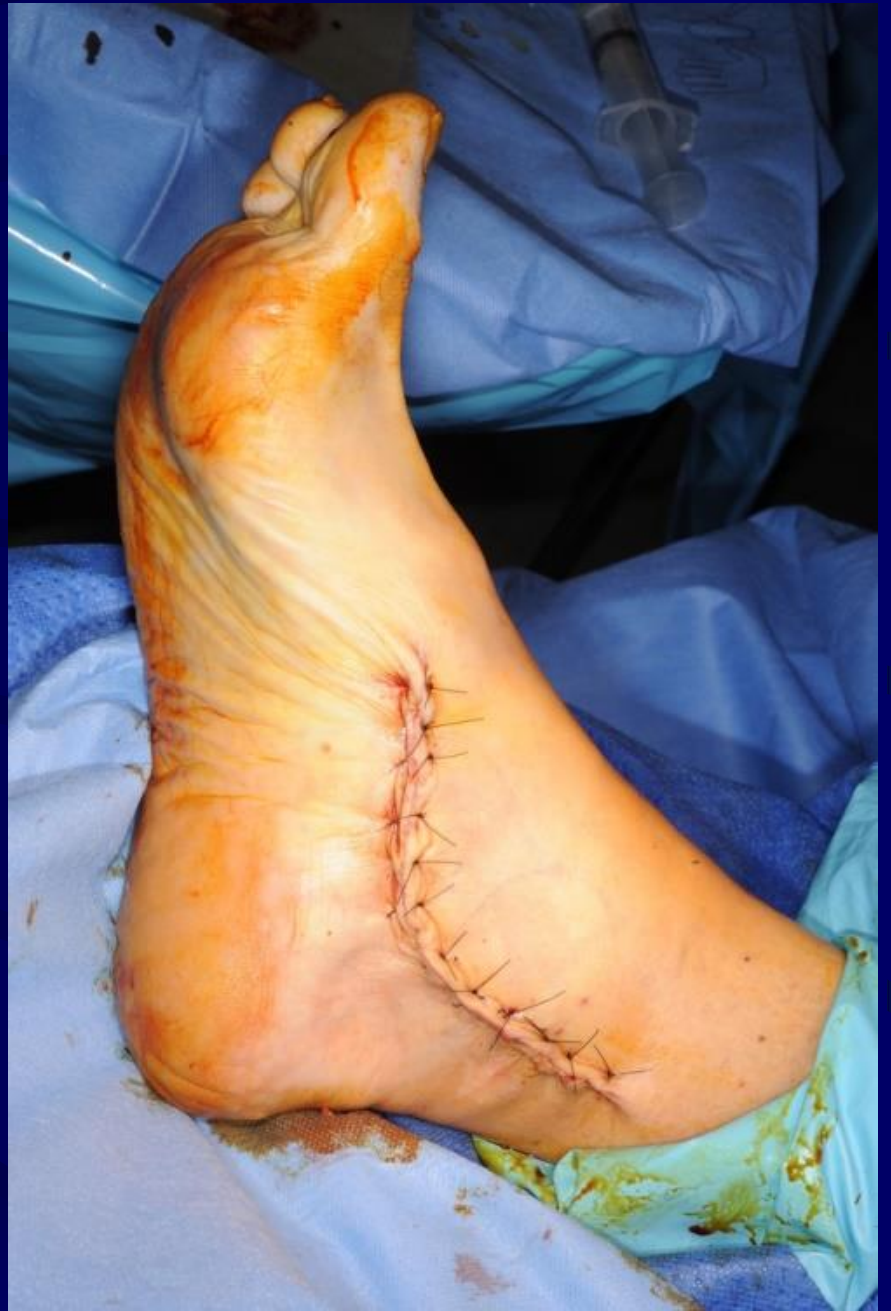
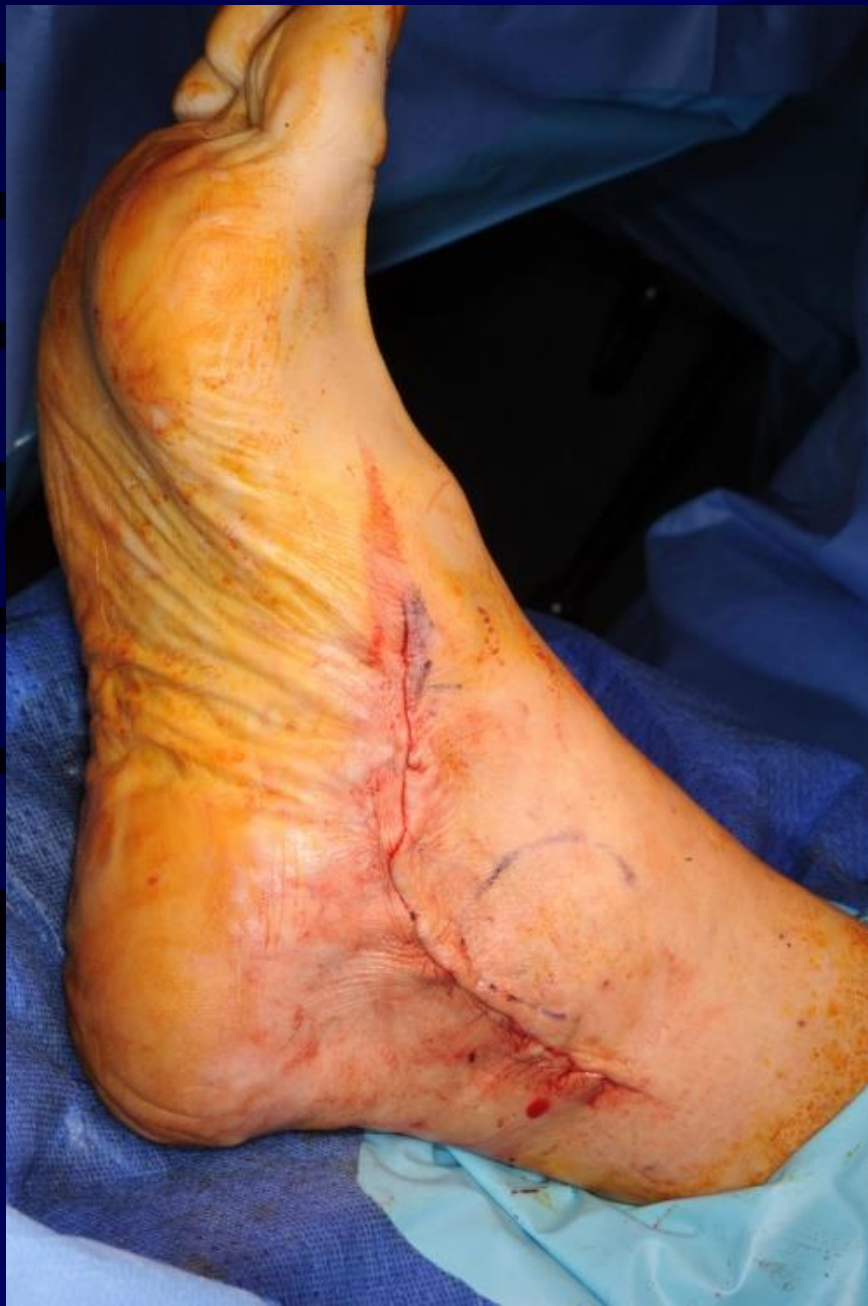




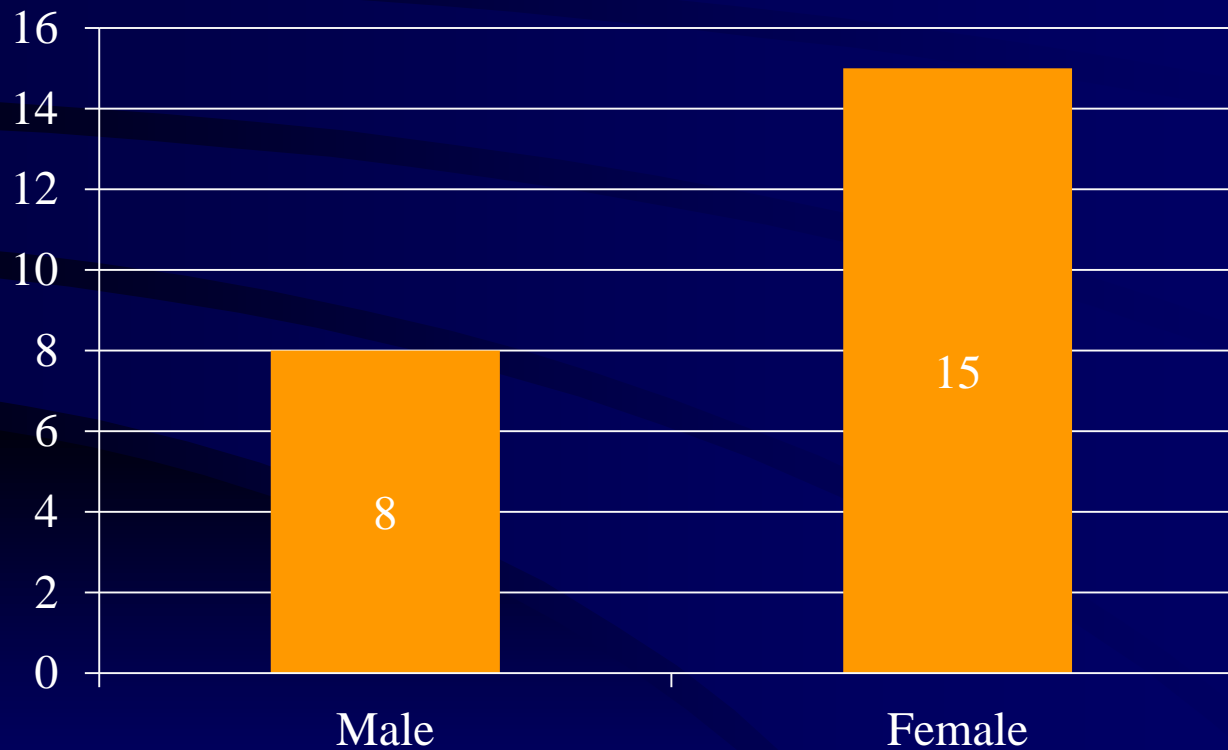






Results

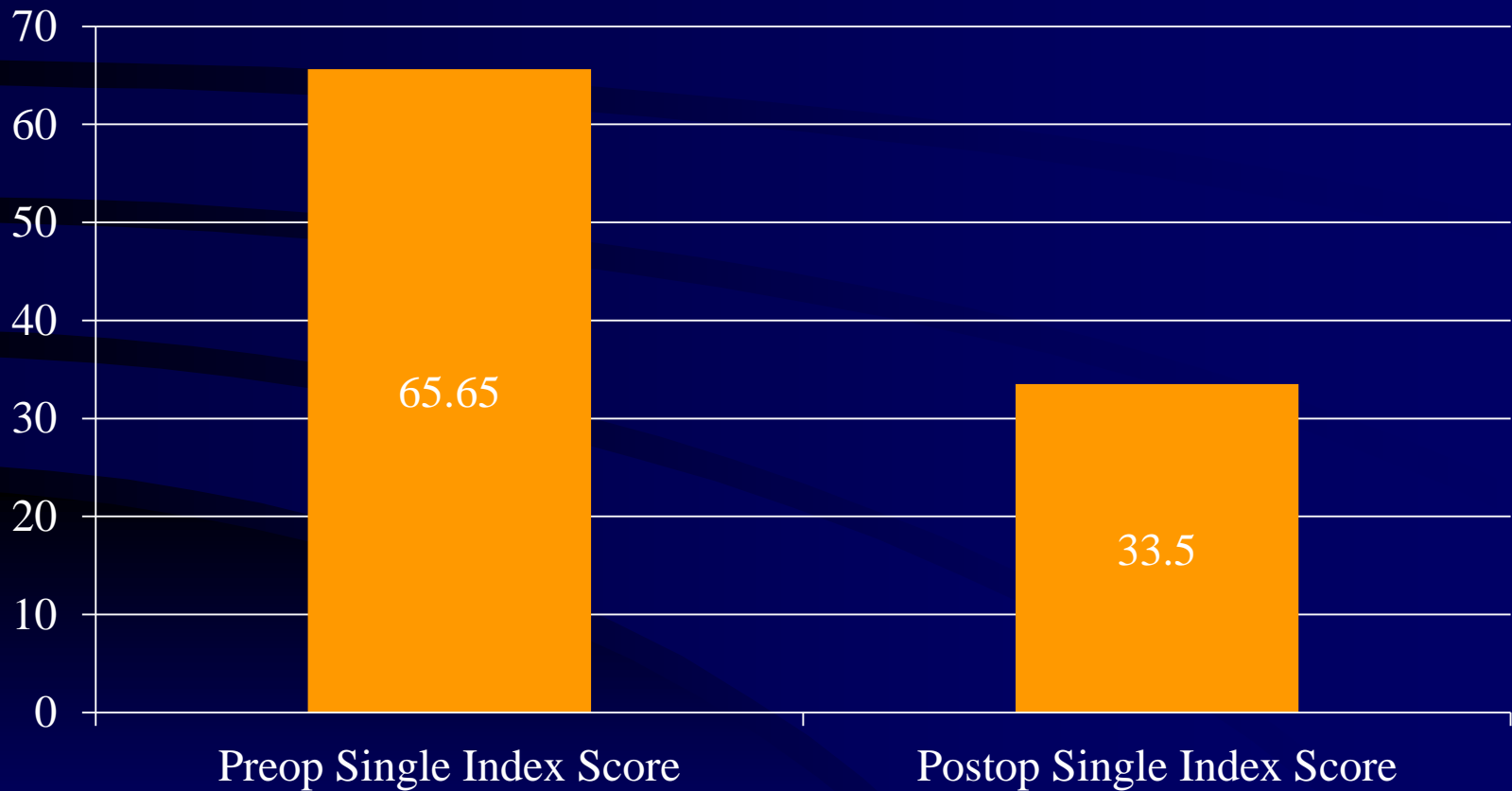
- Total 23 patients



Socio- demographic data

- Age range :36 -77 yrs
- Average age: 58.86 yrs
- Average FU- 25 months(Range: 4-46 m)
- Mobility status- all patients were fit, active and healthy
- Home circumstances- They all were independent and did not require any social support

MOXFQ Single Index Score



Complications

- One patient progressed to stage IIC, for which Evan's procedure was done.
- Patient is doing very well post operative
- Two patients had calcaneal screw removal due to undue prominence

Summary

- Common condition
- Stage IIB AFFD – Controversial Treatment
- Medial sliding calcaneal osteotomy with FDL Transfer is well established procedure
- We have good outcome in our series of Flexible flat foot



Thank you